



UNIVERSITY OF GOTHENBURG




REGION
VÄSTRA GÖTALAND
SAHLGRENKA UNIVERSITY HOSPITAL

HANDENS ANATOMI OCH FYSIOLOGI

SARA CHEVALLEY
ÖVERLÄKARE

HANDKIRURGISKA KLINIKEN, SAHLGRENKA UNIVERSITETSSJUKHUSET



NOMENKLATUR

Hur benämner vi delar av i handen?



dorsalt

volart/palmart

distalt

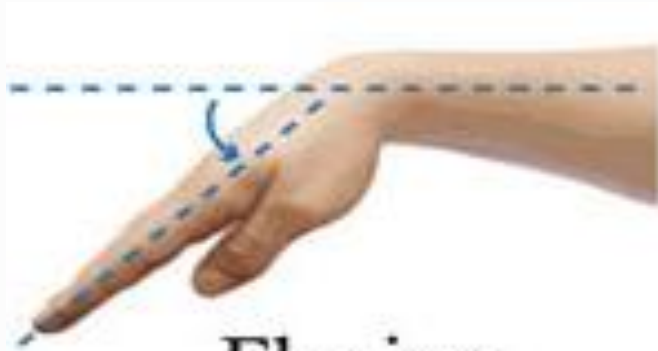


proximalt

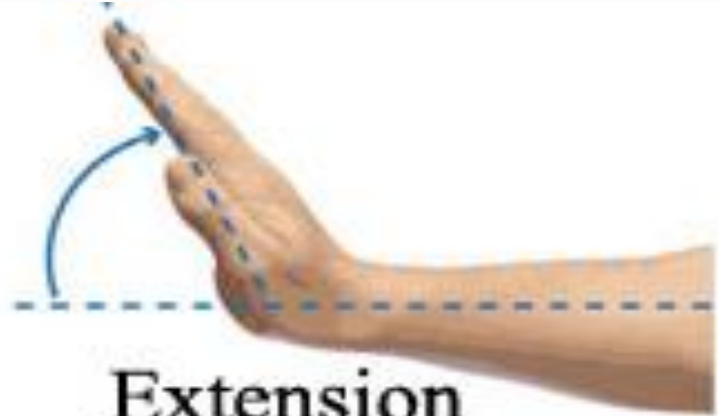
radialt



ulnart

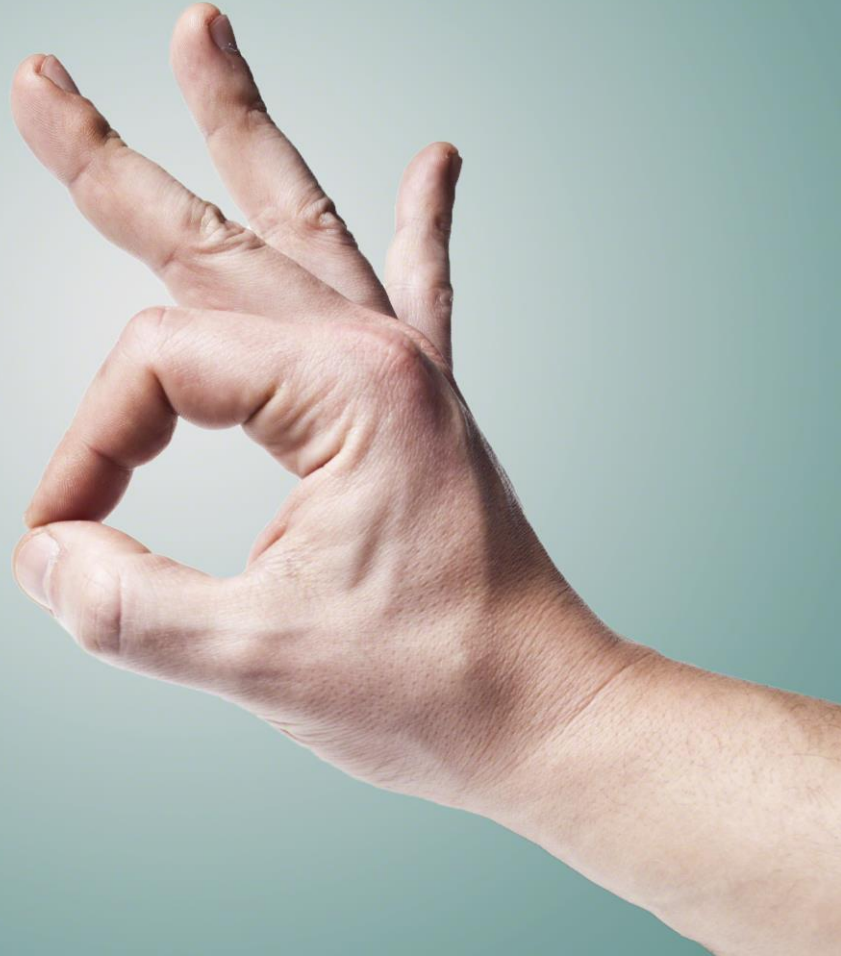

Flexion

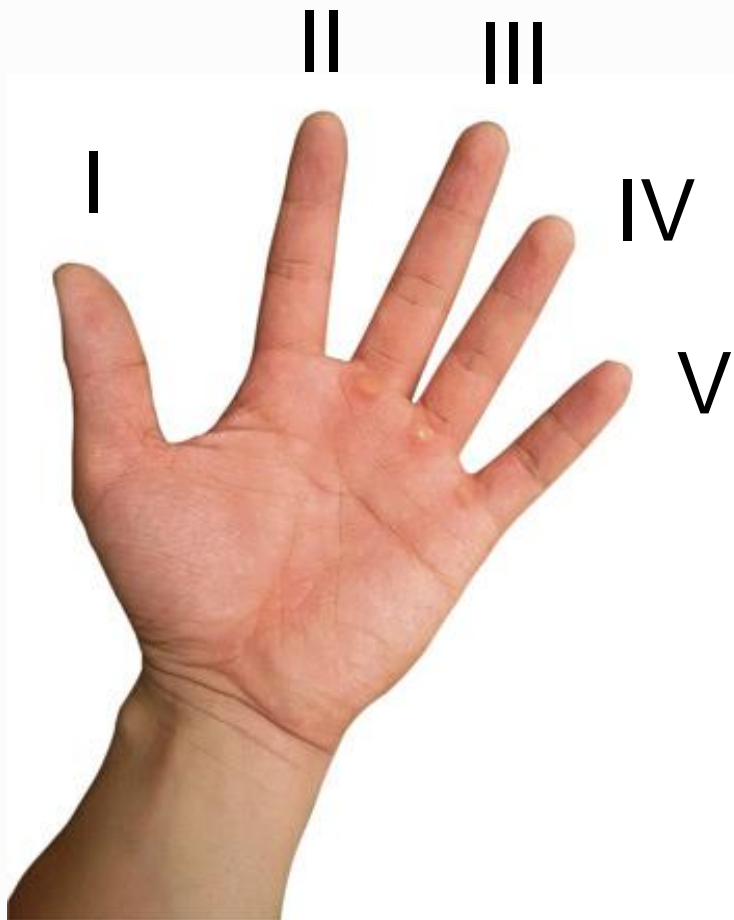


Extension

?



Digitorum (dig)



ANATOMI

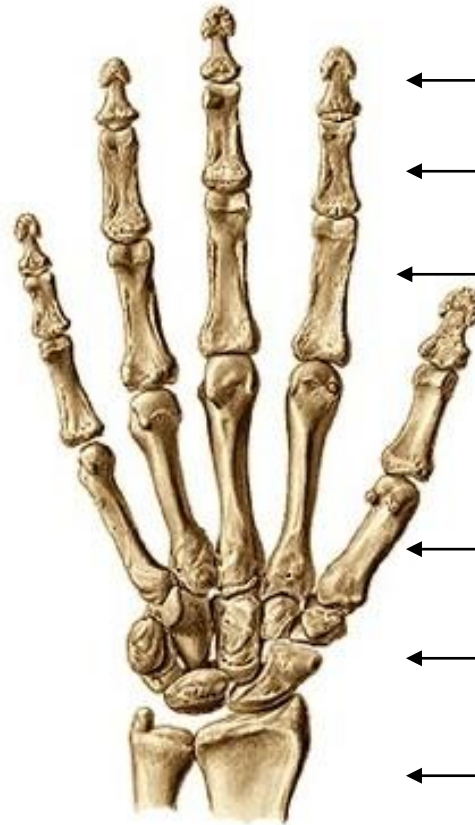Det finns många olika strukturer i en hand...

Ben

Falanger / fingrar

Metacarpus / mellanhand

Carpus / handlov



Distal falang

Mellanfalang

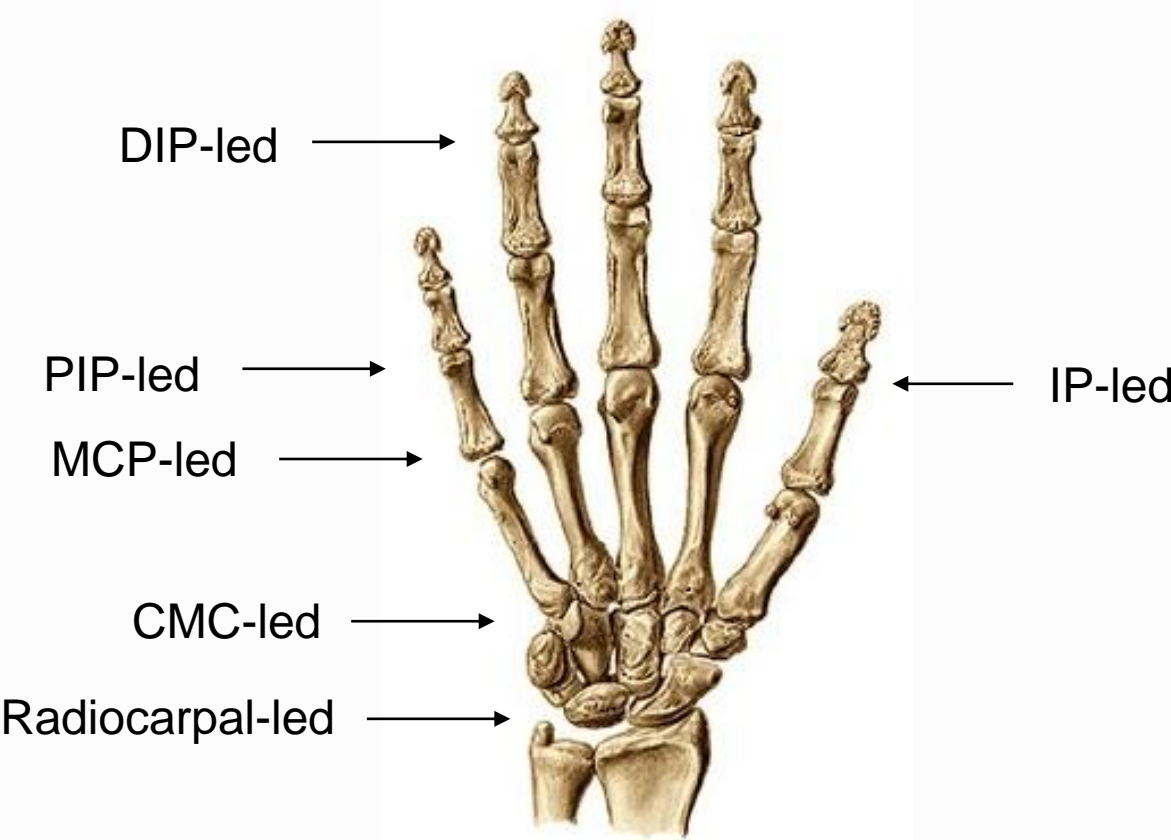
Proximal falang

Metacarpalben

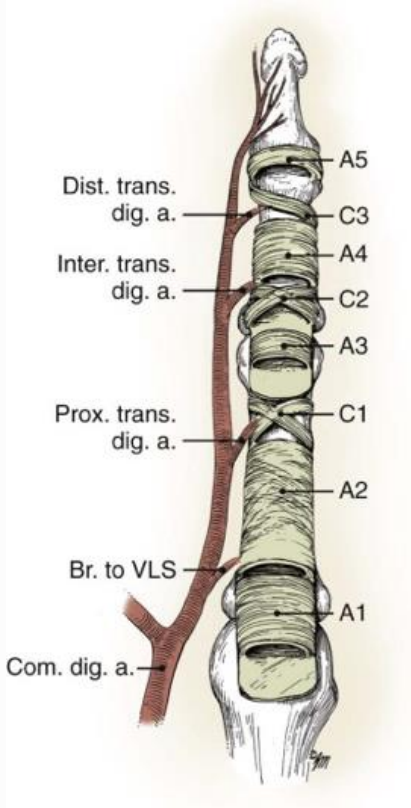
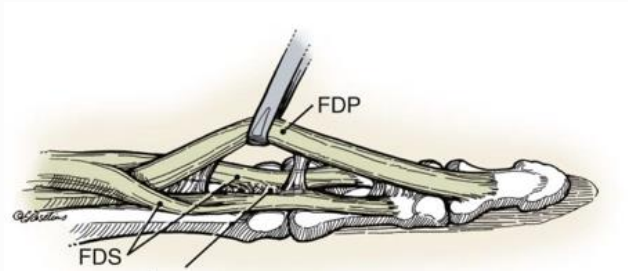
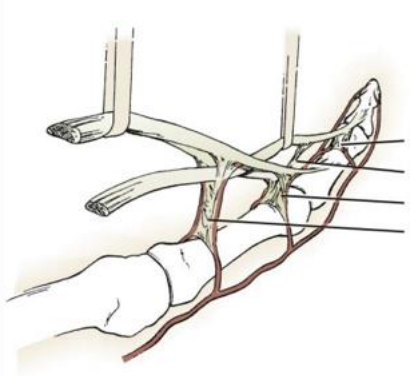
Carpalben

Underarmsben

Leder

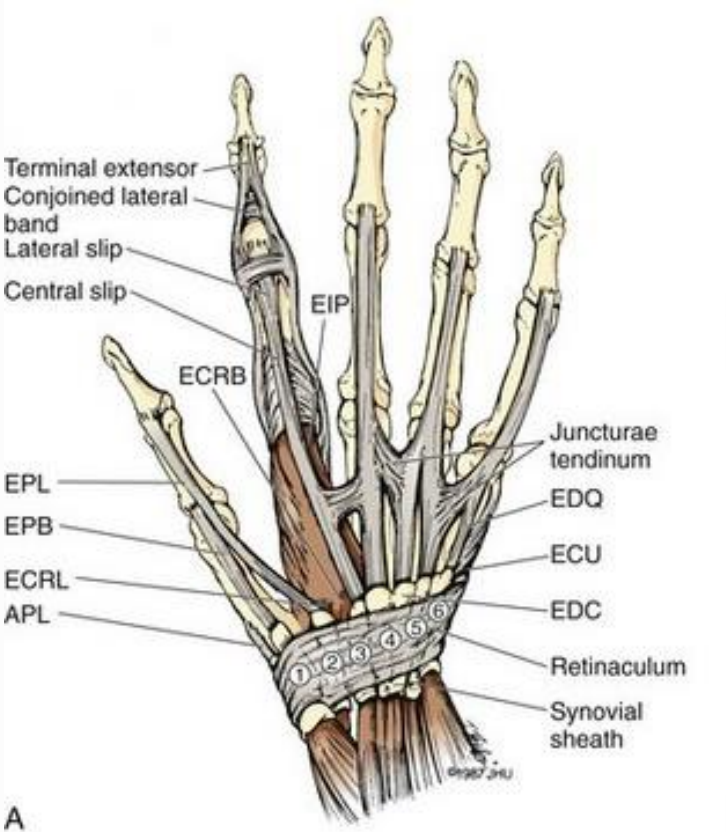


Flexorsenor

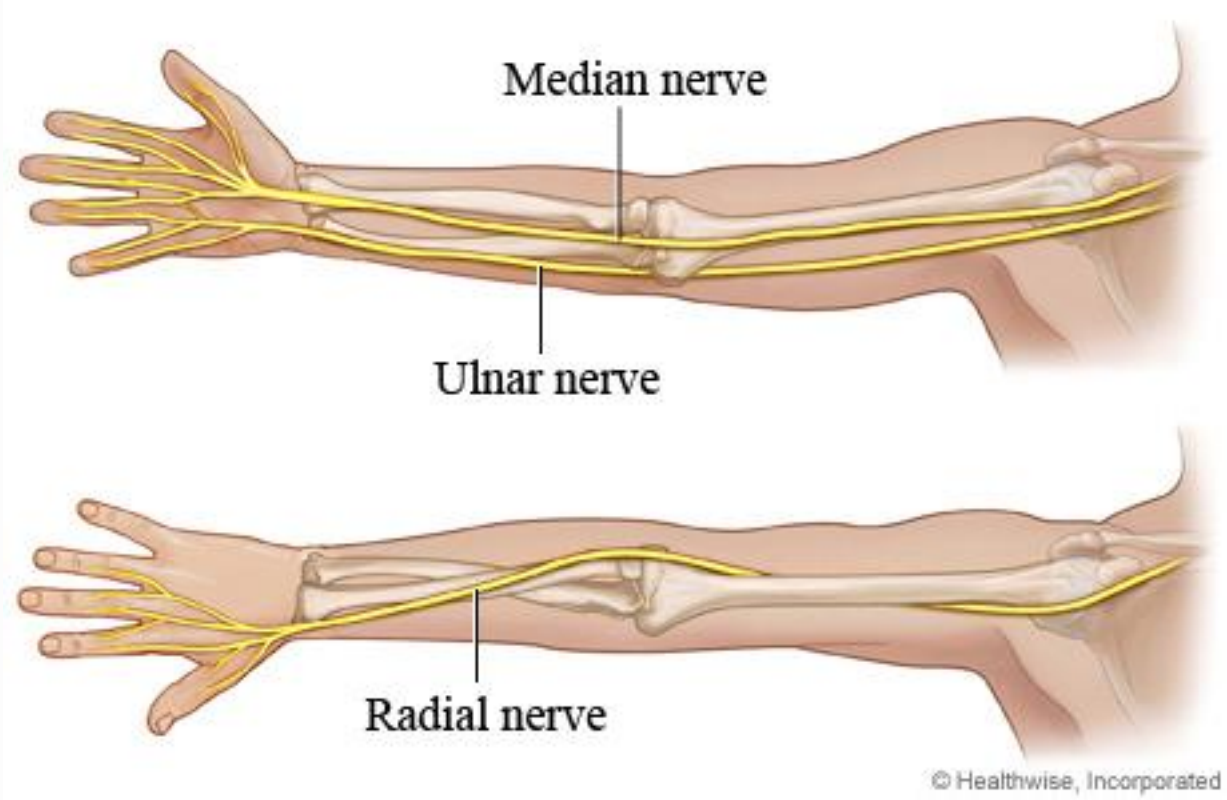


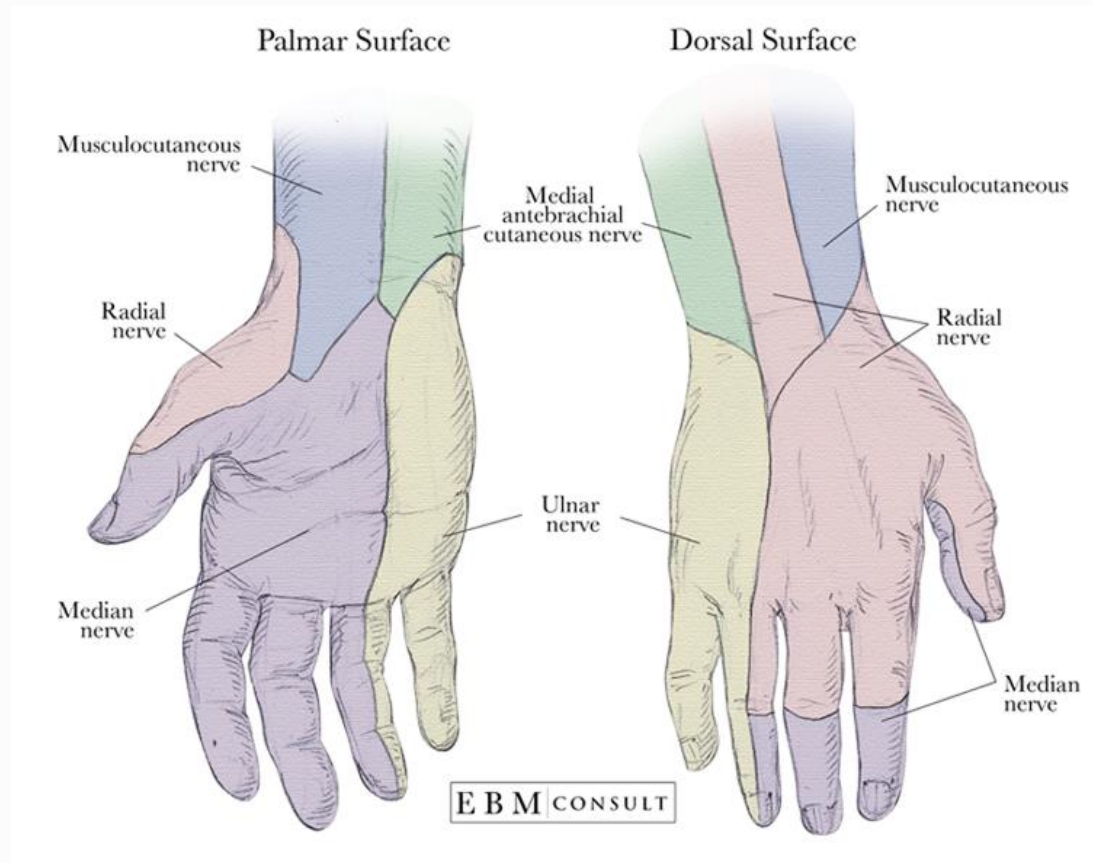
Annularligament

Extensorsensor



Nerver





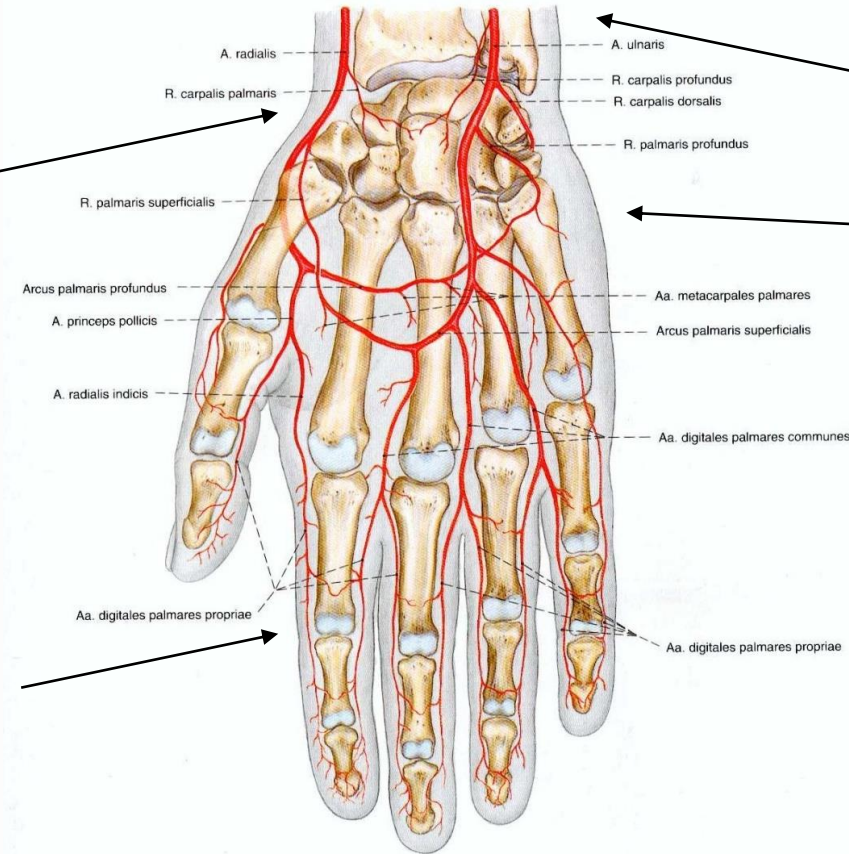
Artärer

Arteria radialis

Digitalartärer

Arteria ulnaris

Kärlarkad



Vener

