

**Blankett - Beställning av utdrag ur IT-system**

Enligt nya dataskyddsförordningen så gäller uppgiftsminimering och tydliga ändamål med hantering av personuppgifter. Ange inte mer personuppgifter i blanketten än vad som är nödvändigt för blankettens ändamål.

**Beställare**Namn Magnus Båth

Område \_\_\_\_\_

Ansvarsnr \_\_\_\_\_

Tfn \_\_\_\_\_

0729618438

Magnus Båth, Avd. f medicinsk strålningsvetenskap, Göteborgs universitet

Extern beställare (namn och kontaktuppgifter): \_\_\_\_\_

magnus.bath@gu.se**Utdrag från** PAX/Elvis Melior Övrigt (ange vilket): \_\_\_\_\_Agfa/Adapt

4

Område(n) \_\_\_\_\_

Radiologi

Avdelnings- eller mottagningsbeteckning(ar) \_\_\_\_\_

 Öppenvård Slutenvård Samtliga avd och mottagningar**Ange vilka uppgifter du vill ta del av**

Lungtomosyntesundersökningar och DT-undersökningar (thorax) utförda inom ramen för SCAPIS Göteborg

**Ange vad uppgifterna ska användas till**

Forskningsprojektet "Utveckling av nya metoder för lungtomosyntes för förbättrad diagnostik inom thoraxradiologi"

 **Identifierbara uppgifter önskas** (uppgifterna kan härledas till person/patient, tänk på att specificera noggrant angående användningsområde ovan då det påverkar sekretessprövningen) **Helt avidentifierade uppgifter önskas** (uppgifterna kan inte härledas till person/patient)**Tidsperiod**

Fr om: \_\_\_\_\_

t o m: \_\_\_\_\_

 Tillfällig beställning Stående beställning önskas, ange intervall och datum \_\_\_\_\_

(I den mån verksamheten har resurser kan stående beställning godkännas, i övrigt gäller ny beställning vid varje uttag)

**Sortering** Personnr Avdelning Annan ordning \_\_\_\_\_**Överlämnande önskas genom** Filöverföring, ange mailadress \_\_\_\_\_

(Gäller endast avidentifierade uppgifter alternativt via krypterat mail inom VGR-domän.)

**Blankett - Beställning av utdrag ur IT-system** Utskrift Annat, ange önskemål

Data kan tas emot på USB-hårddisk

**Bilagor till beställningen:** Etikgodkännande (om ändamålet är forskning) Övrigt (t.ex. uppdragsbeskrivning för kvalitetsuppföljning etc)

Projektbeskrivning

**Enligt angivna villkor, med kännedom om de regler som gäller vid hantering av utdrag ur journalsystem, beställs härmed registerutdrag enligt ovan.**

Datum 220630

Sign  
(Beställarens underskrift)

Namnförtydligande Magnus Båth

**Sekretessprövning har genomförts och beställningen godkänns**

Datum

Sign  
(Verksamhets- respektive områdeschefens underskrift)

Namnförtydligande

För PAX/Elvis sänds denna blankett, efter underskrift, till Elvis kontaktperson, se information nedan.

För Melior sänds denna blankett efter underskrift till områdets rapportskapare, se länk under IT på Sahlgrenska Universitetssjukhusets intranät.

För Orbit, Post-op och IVA, rätt sänds denna blankett efter underskrift till områdets systemsamordnare, se länk under IT på Sahlgrenska Universitetssjukhusets intranät.

**Vid allmänna frågor om utdrag i de olika journalsystemen kan du kontakta:****Elvis:**Johanna Roth, [johanna.roth@vgregion.se](mailto:johanna.roth@vgregion.se)**Melior:**Manaz Aliakbarian, [manaz.aliakbarian@vgregion.se](mailto:manaz.aliakbarian@vgregion.se)**Orbit, Operätt, Post-op och IVA:**

Kontakta områdets systemsamordnare, se länk under IT på Sahlgrenska Universitetssjukhusets intranät.

**Beställning utförd och återsänds till beställare**

Datum

Sign  
(Rapportskapares underskrift)

Namnförtydligande

# List of Signatures Page 1/1

 2021-03857 Beslut godkänd.pdf

Name	Method	Signed at
Helena Cecilia Lindén	BANKID	2021-09-06 21:36 GMT+02



This file is sealed with a digital signature. The seal is a guarantee for the authenticity of the document.

External reference: AF4D67724FC643F689F58CB58D41CC66



**BESLUT**  
2021-08-25

**Sökande forskningshuvudman**  
Västra Götalandsregionen

**Forskare som genomför projektet**  
Magnus Båth

**Projekttitel**  
Utveckling av nya metoder för lungtomosyntes för förbättrad diagnostik inom thoraxradiologi

**Uppgifter om ansökan**  
Ansökan inkom till Etikprövningsmyndigheten 2021-07-02 och blev valid 2021-07-16.

---

Etikprövningsmyndigheten beslutar enligt nedan.

**BESLUT**

Etikprövningsmyndigheten godkänner den forskning som anges i ansökan.

---

På Etikprövningsmyndighetens vägnar

Helena Lindén  
Ordförande

Beslutet har fattats av följande personer:

**Ordförande**  
Helena Lindén, rådmann

**Ledamöter med vetenskaplig kompetens**  
Martin Hägglund, (*fysioterapi, epidemiologi*) vetenskaplig sekreterare  
Magnus Falk (*allmänmedicin, hudcancerdiagnostik/-prevention*)  
Helena Frielingsdorf Lundqvist (*barn- och ungdomspsykiatri/psykiatri, neuro*)  
Anna J Henningsson (*Infektionsmedicin, klinisk mikrobiologi*)  
Marit Karlsson (*geriatrik*)  
Lennart J Nilsson (*pediatrisk allergologi, vaccinologi*)





Håkan Olausson (*klinisk neurofysiologi*), föredragande  
Håkan Pettersson, (*medicinsk strålningsfysik*)

**Ledamöter som företräder allmänna intressen**

Finn Bengtsson  
Bertil Nilsson  
Per-Inge Pettersson  
Katrinn Stagnell

---

**Beslutet sänds till**

Ansvarig forskare: Magnus Båth  
Forskningshuvudmannens företrädare: Annette Lövefors Daun



Development of novel chest tomosynthesis methods for improved diagnostics in thoracic radiology

## **RESEARCH QUESTIONS AND PURPOSE**

Digital chest tomosynthesis (DTS) refers to an imaging technique in thoracic radiology, based on acquiring a number of projection radiographs of the chest at extremely low radiation dose over a limited angular range and using these radiographs for reconstructing slice images of the patient. As opposed to computed tomography (CT) – another imaging technique that can be used to visualize the human chest in slices – the radiation dose from a chest tomosynthesis examination is comparable to that from conventional chest radiography. Also, the tomosynthesis equipment can be produced with relatively small modifications of existing conventional radiography equipment. Chest tomosynthesis can therefore be performed at a low financial cost, has been shown to be easy to implement and results in considerably lower radiation doses than CT, with effective doses for DTS of approx. 0.1 mSv instead of the several mSv typically associated with chest CT. However, the DTS images of today do not reach CT quality, and the acquisition time (10 seconds) makes the technique sensitive to patient motion, e.g. from breathing.

This project addresses the main limitations currently associated with chest tomosynthesis – its limited depth resolution as well as its sensitivity for patient movement – and aims at solving the underlying problems. Furthermore, as the scientific support for the clinical use of DTS is relatively scarce, the project also aims at comparing DTS with CT for several clinical tasks, using a unique data bank of images acquired within a large population study (SCAPIS). The specific research questions are:

1. Can machine learning and advanced image processing be used to improve the diagnostic quality of a chest tomosynthesis examination, for example by improving the depth resolution of the images and reducing motion artefacts?
2. For what clinical detection tasks in chest radiology can DTS replace CT in order to substantially decrease patient radiation doses, examination waiting times and costs while maintaining a sufficient level of diagnostic/clinical information?

The purpose of the present project is to answer these two overarching research questions by performing a number of connected studies, thereby aiming at improving the diagnostics in thoracic radiology.

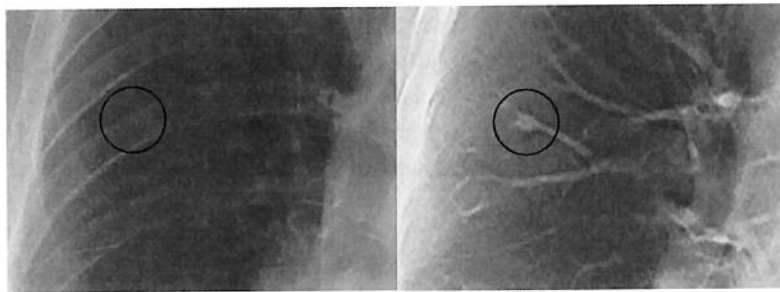
## **BACKGROUND**

For most diagnostic tasks within radiography, CT is regarded as the gold standard. CT images are acquired by rotating a detector and an x-ray source around the patient. Contrariwise, in conventional projection radiography, fixed points are used for the x-ray tube and the detector and therefore there is always a risk that pathologies may be obscured by other overlaying structures in the resulting x-ray images. The diagnostic benefits of CT do however come at a cost: examinations are more expensive and expose the patient to a higher dose of ionizing radiation, increasing the risk of inducing cancer. Therefore, the fact that DTS has the potential to provide the increased diagnostic information obtained by slice images at the low radiation doses, waiting times and costs associated with conventional radiography, has led to the high interest of the technique in thoracic radiology.

Although the theoretical foundation for DTS has been known for a long time, it has only in the last decades been possible to implement it in healthcare. The technique needed modern imaging detectors and availability of computer power, necessary for the advanced reconstruction algorithms, in order to be clinically useful. The reconstructed tomosynthesis slices contain much less of the overlaying anatomical structures than the original projection radiographs. The

## Development of novel chest tomosynthesis methods for improved diagnostics in thoracic radiology

visibility of subtle details, for example lung nodules, is therefore substantially improved compared with conventional chest radiography and leads to improved sensitivity and specificity, as our research group was the first to demonstrate (Vikgren et al 2008) (Figure 1). The technique has reduced many of the obvious detectability problems connected to conventional radiography, thereby increasing the diagnostic information that can be obtained from a radiographic examination. In a large multi-institutional trial we participated in (Dobbins et al 2017), DTS was found to be clearly superior for detection of pulmonary nodules when compared to both conventional chest radiography and dual energy radiography. It has also been reported that in patients with suspected pulmonary lesions on conventional chest radiography, problem-solving using DTS avoided the need for CT in about 75% of the patients (Quaia et al 2013). In addition to the lower financial cost and much lower radiation dose to the patient, the use of DTS instead of CT leads to a substantially higher patient throughput as the examination times and reviewing times are considerably shorter for DTS (Johnsson et al 2014).



**Figure 1.** Cut-out of a conventional posteroanterior chest radiograph of a patient with a lung nodule (barely visible, left) and a slice from a tomosynthesis examination of the same patient (right), exemplifying the increased conspicuity obtained with chest tomosynthesis in comparison with conventional radiography.

Apart from replacing CT for problem solving after inconclusive chest radiography examinations, several studies have indicated that it should be possible to use DTS for many other clinical tasks for which CT is used today. For example, we have previously shown that there is no evident bias between DTS and CT regarding manual measurements of the size of lung nodules (Johnsson et al 2012), indicating the potential of using DTS for follow-up of accidentally detected nodules. Additionally, in our current ALF project, we have demonstrated that DTS could be a low-dose alternative to CT in quantitative estimation of structural lung disease in follow-up of patients with cystic fibrosis (Meltzer et al 2021a, Norrlund et al 2021). This makes DTS a relevant candidate for clinical follow-up of CF patients, as these patients often are young and undergo radiography examinations yearly, resulting in considerable cumulative radiation doses. An analysis of the use of DTS for optimising imaging resources in thoracic radiology indicates that the potential role for DTS to substitute other modalities may be in the order of 20 and 25% of performed conventional radiography and CT examinations, respectively, but that the DTS technique is underused (Pettersson et al 2016). One reason for this underuse is a lack of knowledge regarding for which clinical tasks it is suitable to replace CT with DTS.

Still, for most diagnostic tasks within radiography, CT is regarded as the gold standard because of its ability to map human anatomy in three dimensions, something that DTS has not yet been able to accomplish. Also, DTS images are not straightforward to interpret, and demand a certain amount of re-training of both radiographers and radiologists (Ivarsson et al 2016). We could

## Development of novel chest tomosynthesis methods for improved diagnostics in thoracic radiology

for example recently show that measurement variability limits the agreement between chest tomosynthesis and CT regarding nodule size change for small solid nodules (Meltzer et al 2021b), even if there is no systematic difference (Johnsson et al 2012). The measurement variability restricts the possibility of using chest tomosynthesis for follow-up of accidentally detected nodules – a very important, resource-demanding clinical task for which there has been high hopes that DTS should be able to replace CT. The anisotropic resolution has been identified as the main limitation of the current technique (Johnsson 2014), meaning that the out-of-plane resolution is much worse than the in-plane resolution. This makes it difficult to accurately localize structures in the anteroposterior direction (limited depth resolution). In previous ALF projects we therefore started investigating new reconstruction techniques and we could show that by combining data acquired from two orthogonal acquisitions using advanced image processing techniques, superior visibility was achieved (Arvidsson 2016). An additional limitation with DTS is the acquisition time, leading to the technique being prone to motion artefacts, mainly from breathing. However, each of the 60 individual projection radiographs is acquired during a very short time (ms), indicating that it should be possible to employ computer analysis of the movement of image structures prior to reconstruction. In the proposed project we therefore intend to pursue the use of advanced image analysis and machine learning techniques to find solutions to the identified limitation in DTS and use these techniques to obtain reconstructed DTS images with improved diagnostic quality.

### **DESIGN, METHODS, WORK PLAN AND FEASIBILITY**

#### ***Overall description of work plan***

This project consists of two different types of studies, grouped into two work packages. The first work package concerns the development and application of advanced image processing and machine learning techniques, aiming at improving the DTS technique. In the second work package, mainly based on the large database of image data acquired within SCAPIS, it will be investigated to what extent DTS can replace CT in chest radiology for detection of pathology. These studies are built on previously developed methodology for conducting observer performance studies (designed and/or implemented in-house) and aims at improving the scientific foundation for the clinical use of DTS. Combined, the work packages will lay the foundation for an improvement of thoracic radiology through a better-founded and more efficient use of DTS in the clinical workflow.

#### ***Methods and Equipment***

Originally based on a research agreement between Sahlgrenska University Hospital and GE Healthcare, Sahlgrenska University Hospital now has had access to the DTS technique for more than a decade and the hospital has established itself as one of the world-leading research sites for optimisation, evaluation and improvement of the technique. In combination with previously developed in-house software for efficiently conducting observer performance studies (ViewDEX and VGC Analyzer – see below), installed on high-performance workstations, the research group has access to the necessary combination of hardware and software for successfully conducting experimental and clinical research on DTS, as proven by numerous previous publications.

#### ***SCAPIS***

The Swedish CARDioPulmonary bioImage Study (SCAPIS) is a prospective observational study of a large, randomly selected, sample from the general population. SCAPIS combines the use of new imaging technologies, advances in large-scale ‘omics’ and epidemiological analyses to extensively characterize a Swedish cohort of 30000 men and women aged between 50 and 64 years (Bergström et al 2015). In the SCAPIS study in Gothenburg, 5000 research subjects were

## Development of novel chest tomosynthesis methods for improved diagnostics in thoracic radiology

examined with CT and DTS. Of special relevance to the present application is the fact that the DTS examinations were performed on the same day as the CT examinations, meaning that they together form a huge database of paired examinations, making a large number of different study types and analyses feasible.

### *Infrastructure for conducting observer performance studies*

ViewDEX (Viewer for Digital Evaluation of X-ray Images) is an image viewer that has been especially designed to facilitate image perception and observer performance studies within medical imaging, developed by our research group. In order to meet the demands of new imaging technology, our research group is constantly developing and improving ViewDEX. Currently, we are a research partner of the large-scale Horizon 2020 project “Implications of Medical Low Dose Radiation Exposure” (MEDIRAD), consisting of 34 European research partners with a total budget of almost 10 million euro. Our main task in MEDIRAD has been the modification of ViewDEX for improved visualisation of 3D imaging data. This development was recently completed (Svalkvist et al. 2021) and is of major importance for the planned observer performance studies in the presently proposed project. We have also developed software dedicated to visual grading characteristics (VGC) studies (VGC Analyzer), enabling proper statistical analysis of VGC data (Båth and Hansson 2016). VGC analysis is an image quality evaluation technique previously developed by our group that can be used to correctly analyse data from image quality evaluations where observers give subjective opinions about the image quality (Båth and Månsson 2007). During the previous ALF project, we performed an extensive evaluation and validation of VGC Analyzer (Hansson et al 2021). The combination of ViewDEX and VGC Analyzer has proven extremely valuable for conducting imaging research and imaging optimisation studies in a clinical environment, as indicated by the major spread of these software tools. ViewDEX has been downloaded by more than 1000 medical imaging researchers from over 40 countries, and the newer software VGC Analyzer is already in use by medical imaging researchers from over 20 countries worldwide.

### *Observer performance studies – design and statistical considerations*

Observer performance studies using expert observers are a fundamental part of medical imaging research. In this project, a group of radiologists with clinical experience of DTS and CT will participate as observers in all studies. The images will be presented to the observers in random order using ViewDEX, thus minimizing the risk of bias. Both detection tasks [using jackknife free-response receiver operating characteristics (JAFROC) analysis] and rating tasks (using VGC analysis) will be included. Being a free-response ROC method, JAFROC can be used to perform a detection study at the lesion level instead of at the patient level (as is the case for standard ROC) and it has been shown that JAFROC analysis is the statistically most efficient ROC method (Chakraborty 2006). The increased statistical power resulting from such an analysis enables a limited patient image material to be more efficiently used for study purposes. Based on the statistical analysis of our previously performed detection study in DTS using JAFROC analysis (Vikgren et al 2008), we have conducted power calculations. According to these calculations, a sample size of at least 70 cases is necessary in order to find an effect size corresponding to a difference in the JAFROC figure-of-merit of 0.08 (a clinically relevant difference) at an alpha level of 0.05 and a power of 0.80, if four observers are used. We therefore aim at including at least 100 cases in each clinical detection study, if possible, and using at least five experienced radiologists as observers. Regarding the design and statistical analysis of JAFROC studies, we are in close contact with the developer of JAFROC analysis (prof. Dev Chakraborty, University of Pittsburgh). Regarding VGC analysis, experience has shown that the inclusion of between 20 and 50 cases results in a sample size large enough to achieve statistically significant results for clinically relevant differences in image quality. This clinical

## Development of novel chest tomosynthesis methods for improved diagnostics in thoracic radiology

experience matches a recent evaluation of the statistical properties of VGC analysis, as an extensive study determining the statistical properties of VGC analysis has shown that at least 25 cases are necessary to achieve robust results (Hansson et al 2021). Standard power calculations are difficult to apply to VGC analysis as the inter-observer correlation strongly affect the results and it is well known that the agreement between different observers is notoriously challenging to predict. However, pilot studies will be conducted, where relevant, to make sure that the data material is sufficient to achieve the desired statistical precision.

### *Machine learning*

Machine learning is a term used to describe the use of computer algorithms that automatically improve through “experience” and by training on data sets to solve a specific problem. It is sometimes referred to as artificial intelligence (AI), although the latter term is much broader and more imprecise. Machine learning has a long history, but its tremendous success in the last years is an effect of the possibility of employing ‘deep learning’, which is computational technique where the structure of the computer algorithms that are trained is based on the network of neurons in the human brain (resulting in so-called artificial neural networks). For analysing image data, a special class of neural networks is the convolutional neural network (CNN). In a CNN, the structure of the artificial neurons is constructed to resemble that of the human visual cortex. Deep-learning techniques are extremely computationally intensive and require both large sets of training data and high-performance computers and it is only during the last years that single research groups have been able to acquire the necessary computer power to perform deep learning in an effective way.

In the present project, supervised deep-learning techniques will be used to improve DTS. In supervised learning, the algorithm is trained to produce the desired output from a given input based on example input-output pairs. Supervised learning requires large data sets for the trained algorithm to be able to produce accurate results, which in the present project is fulfilled by the inclusion of almost 5000 paired (CT and DTS) examinations of the same research subjects performed on the same day. The main architecture that will be used is U-Net, a CNN developed for biomedical image segmentation that has been modified to work with fewer training images and still produce precise results (Ronneberger et al 2015).

### *Work plan*

#### *Work package 1 – Further development of chest tomosynthesis using machine learning*

##### Study 1. Generation of “pseudo-CT images” from chest tomosynthesis data

As described above, DTS combines the advantages of projection radiography (relatively low technical complexity and lower radiation dose) with those of CT (3D imaging with limited problem of superimposition of structures). However, current reconstruction of DTS suffers from a limited depth resolution, limiting the possibility to accurately determine the position and size of structures. In Study 1, we aim at addressing this problem using machine learning, where a convolution neural network will be trained to generate CT-like images from DTS data.

Image data from almost 5000 research subjects, examined with both CT and DTS within SCAPIS Göteborg, will be used. These data offer a unique opportunity for machine learning with the DTS images as the conditional input paired with the true corresponding CT images of the same subject. This way the system will learn how to translate the former into the latter. Recent work has yielded impressive results in many similar tasks such as image fusion (Joo et al 2018) and image-to-image translation (Zhu et al 2017). The goal of this project is to develop and validate an algorithm that can output CT quality images, based on the more available and simpler technology of DTS.

## Development of novel chest tomosynthesis methods for improved diagnostics in thoracic radiology

Two different machine learning techniques will be used. Training a “standard” CNN (U-Net), will be the main path, but as an alternative we also propose to close the gap between the two separate imaging modalities through a recent advance in deep learning, namely generative adversarial networks (GAN). GANs were originally proposed by Goodfellow et al. (2014) and are a technique for image generation. The system contains two principal components: a discriminator, which distinguishes real images from fake ones, and a generator, which generates fake images that look real. The two components are played against each other. Through this adversarial training procedure, the generator produces outputs whose distribution gets closer to the real data distribution. Training a GAN is an interesting complement to standard machine learning, as it has the potential to generate a set of images that may aid the radiologist when interpreting the data from a DTS examination.

In Study 1, the first task will be to build and train the networks (U-Net and GAN) to output synthetic CT images (“pseudo-CT”) from an input of DTS data. The output images from these networks will then be included in observer performance experiments in which the performance of radiologists in detecting relevant pathology (see Work package 2) and their assessment of the image quality will be studied and compared with the original DTS examinations. The outcome of the original CT examinations will be the reference truth. Both JAFROC studies and VGC-analysis will be used to compare the imaging techniques.

Study 1 is easily identifiable as a high-risk/high-reward study, as the success of the study cannot be proven beforehand. However, even if the study will not be completely successful in generating images of CT quality, the study will give valuable knowledge about the limitations of the content of DTS images, which will be of high clinical value for radiologists interpreting these images in routine clinical work.

### Study 2. Motion tracking for reduction of motion artefacts

In DTS, the 60 acquired projection radiographs are used to reconstruct slices of the chest, ideally under the condition that the patient is stationary during the image acquisition. Patient movement during the acquisition results in motion artefacts in the reconstructed slices, which may lead to subdiagnostic quality and the necessity of retakes (unnecessary radiation exposure). Also, patients that due to age or lung disease are unable to hold their breath for 10 s – not uncommon at a thoracic radiology department – are presently disqualified for a DTS examination. The sensitivity to motion artefacts has been described as one of the main limitations of DTS (Johnsson et al 2014).

In Study 2, we intend to develop automated motion tracking for reduction of motion artefacts, predominantly from breathing. The idea behind this study is based on the fact that, even though the acquired low-dose projection radiographs in DTS are noisy, high-density structures, such as the diaphragm, are well visualized and easy to localize exactly using edge detection algorithms (see Preliminary results). Since the geometry of the acquisition is well known, it should therefore be possible to identify single projection radiographs in which a specific high-density structure is in a non-expected position – indicating patient movement. If the affected projection images can be identified and removed before reconstruction, DTS images with reduced motion artifacts can be obtained

In this study, the method proposed above will be implemented and evaluated, using image data in which motion artefacts from e.g. breathing have been identified. Parameters to study are e.g. what image structures to analyse in order to detect motion (the diaphragm is a good candidate),

## Development of novel chest tomosynthesis methods for improved diagnostics in thoracic radiology

what deviation from the ideal position that is tolerable, and what number of radiographs that can be corrected or removed. Based on the reconstructed image material, a VGC study will be conducted to determine the optimum value of these parameters, using quality criteria developed for assessing artefacts. In this way we hope to reduce the sensitivity of the technique for patient motion, solving a present limitation of DTS. We will also investigate if it is possible to use machine learning (train a CNN) to both identify which projections that should be removed and to artificially generate replacement projections (cf. Study 3). Using VGC analysis, it will also be investigated if the original projection radiographs themselves may be of clinical value during image review.

### Study 3. Generation of synthetic intermediate projections

The radiation dose of the DTS examinations is directly proportional to the number of acquired projections, and it is therefore of interest to investigate if the number of acquired projections can be decreased by instead generating synthetic intermediate projections using machine learning. This technique was recently proposed in single-photon emission computed tomography (SPECT), where a U-Net successfully could be trained to reduce the number of acquired projections (Rydén et al 2021). In Study 3, this technique will be applied to DTS. The DTS examinations performed within SCAPIS will be used for this task, meaning that the U-Net can be trained on a huge image data set. In the study, it will be investigated to what extent generated intermediate projections can replace actual acquisitions. The quality of the reconstructed images will be evaluated using VGC analysis, in which radiologists will rate both the reproduction of important anatomical structures and the presence of possible image artefacts. Aside from leading to a reduced patient radiation dose, a reduction of the number of acquired projections also has the potential to decrease the acquisition time, thereby reducing the problem of motion artefacts associated with DTS.

### *Work package 2 – Evaluation of the accuracy of chest tomosynthesis in detecting disease occurring in a population study (SCAPIS)*

In Work package 2, several studies will be conducted to investigate to what extent DTS could replace CT in the task of detecting different types of chest pathology. The basis for these studies will be the almost 5000 paired CT and DTS examinations performed within SCAPIS Göteborg. What types of pathology that will be investigated in the substudies depends on the outcome of the CT examinations performed and will thus be based on the clinical findings in SCAPIS, in order to ensure that a sufficient number of cases are included in each substudy. The CT examinations will be accessible from the SCAPIS data bank during autumn 2021, coinciding well with the start of the present project. However, the prevalence of certain conditions can already be foreseen. For example, pulmonary nodules and emphysema can each be expected to occur in around 10% of the examinations. Regarding emphysema, the DTS examinations will be prospectively analysed in the same way as the chest CT examinations in the SCAPIS study, i.e. the same questions regarding emphysema score will be answered by DTS observers as the CT observers (DTS and CT cases will be assigned to different observers). The truth will be established by a consensus reading of the CT images by at least two experienced thoracic radiologists, taking into account additional diagnostic information made available by the pulmonary function tests performed within the SCAPIS project.

For lung nodules, it can be anticipated that the sheer size of the acquired image data material will enable us to perform studies at a much more detailed level than previously. For example, we intend to conduct a JAFROC study to determine to what extent the detectability of a lung nodule is dependent on its location, size and composition, giving valuable information regarding under what conditions it may be motivated to use DTS clinically.

## Development of novel chest tomosynthesis methods for improved diagnostics in thoracic radiology

For other pathology of sufficient prevalence in the data material (for statistical considerations, please refer to ‘Observer performance studies’ above), JAFROC studies will be conducted to compare the detectability of DTS with CT. Additionally, VGC studies will be performed for characterizing the visibility of anatomy. Combined, these studies will enable us to recommend for what clinical tasks it is suitable to use DTS instead of CT, leading to shorter patient waiting times, lower patient radiation doses and less expensive examinations, thus optimising the use of the resources available in a thoracic radiology department for improved patient care.

### **Research group**

The core of the research group at Sahlgrenska University Hospital/University of Gothenburg concerned with DTS and headed by the main applicant consists of radiologists, medical physicists, computer engineers and PhD students. The research group is world leading in the field of evaluation and optimisation of DTS and has e.g. received multiple grants from the Swedish Research Council for this purpose. For the present project, additional relevant expertise has been added to the group by establishing collaboration with Rolf Heckemann, professor in Medical Imaging and Image Analysis at MedTech West/Sahlgrenska Academy and Jonas Ivarsson, professor of Informatics at the Department of Applied Information Technology. Prof. Heckemann is experienced in the application of machine learning for medical image analysis and was recently awarded with a position on the 2020 list of prominent research projects, published by the Royal Swedish Academy of Engineering Sciences (IVA). Prof. Ivarsson is currently studying how to design AI systems so to operate in the context of human users. The contributions of Heckemann and Ivarsson will be essential for the AI development in the present project, especially for Study 1.

### **REFERENCES**

- Arvidsson et al. Image fusion of reconstructed digital tomosynthesis volumes from a frontal and a lateral acquisition. *Radiat. Prot. Dosim.* 169:410-415 (2016).
- Bergström et al. The Swedish CARDioPulmonary BioImage Study: objectives and design. *J. Intern. Med.* 278:645-659 (2015).
- Båth&Månsson. Visual grading characteristics (VGC) analysis: a non-parametric rank-invariant statistical method for image quality evaluation. *Br. J. Radiol.* 80:169-176 (2007).
- Båth&Hansson. VGC Analyzer: a software for statistical analysis of fully crossed multiple-reader multiple-case visual grading characteristics studies. *Radiat. Prot. Dosim.* 169:46-53 (2016).
- Chakraborty. Analysis of location specific observer performance data: validated extensions of the jackknife free-response (JAFROC) method. *Acad. Radiol.* 13:1187-1193 (2006).
- Dobbins et al. Multi-institutional evaluation of digital tomosynthesis, dual-energy radiography, and conventional chest radiography for the detection and management of pulmonary nodules. *Radiology* 282:236-250 (2017).
- Goodfellow et al. Generative adversarial nets. arXiv:1406.2661v1 (2014).
- Hansson et al. Evaluation of VGC Analyzer by comparison with gold standard ROC software and analysis of simulated visual grading data. *Radiat. Prot. Dosim.* (published online 2021)
- Ivarsson et al. The application of improved, structured and interactive group learning methods in diagnostic radiology. *Radiat. Prot. Dosim.* 169:416-421 (2016).
- Johnsson et al. Pulmonary nodule size evaluation with chest tomosynthesis. *Radiology* 265:273-282 (2012).
- Johnsson et al. Chest tomosynthesis: technical and clinical perspectives. *Semin. Respir. Crit. Care Med.* 35:17-26 (2014).

## Development of novel chest tomosynthesis methods for improved diagnostics in thoracic radiology

Joo et al. Generating a fusion image: one's identity and another's shape. arXiv:1804.07455v1 (2018)

Meltzer et al. Quantification of pulmonary pathology in cystic fibrosis-comparison between digital chest tomosynthesis and computed tomography. *Radiat. Prot. Dosim.* (published online 2021a)

Meltzer et al. Surveillance of small, solid pulmonary nodules at digital chest tomosynthesis: data from a cohort of the pilot Swedish CARdioPulmonary bioImage Study (SCAPIS). *Acta Radiol.* 62:348-359 (2021b).

Norrlund et al. Evaluation of two chest tomosynthesis cystic fibrosis scoring systems using high-resolution computed tomography Brody scoring as reference. *Radiat. Prot. Dosim.* (published online 2021)

Petersson et al. An analysis of the potential of chest tomosynthesis in optimising imaging resources in thoracic radiology. *Radiat. Prot. Dosim.* 169:165-170 (2016).

Quaia et al. Digital tomosynthesis as a problem-solving imaging technique to confirm or exclude potential thoracic lesions based on chest X-ray radiography. *Acad. Radiol.* 20:546-553 (2013).

Ronneberger et al. U-Net: Convolutional networks for biomedical image segmentation. arXiv:1505.04597 (2015).

Rydén et al. Deep-learning generation of synthetic intermediate projections improves <sup>177</sup>Lu SPECT images reconstructed with sparsely acquired projections. *J. Nucl. Med.* 62:528-535 (2021).

Svalkvist et al. ViewDEX 3.0—Recent development of a software application facilitating assessment of image quality and observer performance. *Radiat. Prot. Dosim.* (published online 2021)

Vikgren et al. Comparison of chest tomosynthesis and chest radiography for detection of pulmonary nodules: human observer study of clinical cases. *Radiology* 249:1034-1041 (2008).

Zhu et al. Unpaired image-to-image translation using cycle-consistent adversarial networks. arXiv:1703.10593 (2017).